

# Hypothermic Circulatory Arrest in Median Sternotomy Hemorrhage During Redo Aortic Surgery

Tiansheng Tang<sup>1#</sup>, MD; Changjuan Wu<sup>2#</sup>, MD; Jianshi Liu<sup>3</sup>, MD; Kaitao Jian<sup>3</sup>, MD; Wei Liu<sup>3</sup>, MD; Weiyong Sheng<sup>1</sup>, MD

<sup>1</sup>Department of Cardiovascular Surgery, The First Affiliated Hospital of Wannan Medical College (Yijishan Hospital of Wannan Medical College), Wuhu, Anhui, People's Republic of China.

<sup>2</sup>Department of Pharmacy, Wannan Medical College, Wuhu, Anhui, People's Republic of China.

<sup>3</sup>Department of Cardiovascular Surgery, DeltaHealth Hospital, Shanghai, People's Republic of China.

<sup>#</sup>These authors contributed equally to this work.

This study was carried out at the Department of Cardiovascular Surgery, The First Affiliated Hospital of Wannan Medical College (Yijishan Hospital of Wannan Medical College), Wuhu, Anhui, People's Republic of China.

## ABSTRACT

**Introduction:** This study summarizes the clinical data of patients who developed sternotomy hemorrhage during redo aortic surgery and analyzes the clinical experience of using hypothermic circulatory arrest.

**Methods:** We retrospectively analyzed the medical records of patients who developed sternotomy hemorrhage during redo aortic surgery from May 2018 to August 2021. General anesthesia with single-lumen tracheal intubation was used. Femoral artery, vein, and superior vena cava cannulation were used if cardiopulmonary bypass was required according to the situation, and right superior vein or apical cannulation was selected for left heart drainage.

**Results:** A total of 11 patients were enrolled in this study, comprising nine males and two females, with an average age of 44.3±16.7 years. All cases were successfully

completed without cerebrovascular complications or paraplegia. Two patients died during hospitalization, two patients died during the follow-up after discharge, and the remaining patients are recovering well.

**Conclusion:** The femoral-femoral bypass with hypothermic circulatory arrest technique is a safe and reliable method to use in cases of sternotomy hemorrhage during redo aortic surgery.

**Keywords:** Sternotomy. Superior Vena Cava. Catheterization. Intratracheal Intubation. Drainage. Patient Discharge.

## Abbreviations, Acronyms & Symbols

AAA	= Ascending aortic aneurysms	DM	= Diabetes mellitus
AAR	= Ascending aortic repair	F	= Female
AD	= Aortic dissection	HCA	= Hypothermic circulatory arrest
AI	= Aortic insufficiency	HF	= Heart failure
AV	= Aortic valve	M	= Male
AVR	= Aortic valve replacement	MHCA	= Moderate hypothermic circulatory arrest
BMI	= Body mass index	MI	= Mitral insufficiency
CPB	= Cardiopulmonary bypass	MVR	= Mitral valve replacement
CTA	= Computed tomography angiography	TEVAR	= Thoracic endovascular aortic repair
DHCA	= Deep hypothermic circulatory arrest		

Correspondence Address:

**Weiyong Sheng**

 <https://orcid.org/0000-0002-3154-0064>

Department of Cardiovascular Surgery, The First Affiliated Hospital of Wannan Medical College (Yijishan Hospital of Wannan Medical College)

No. 2 West Zheshan Road, Wuhu, Anhui, People's Republic of China

Zip Code: 241001

E-mail: shengweiyong1014@163.com

Article received on April 9<sup>th</sup>, 2022.  
Article accepted on March 16<sup>th</sup>, 2023.

## INTRODUCTION

With advancement of cardiac surgical techniques and increased life expectancy, the number of patients who may require redo aortic surgery is increasing. Due to postoperative changes in tissue adhesions, anatomical structures, and cardiac physiologic functional status, redo aortic surgery remains a great challenge for cardiovascular surgeons<sup>[1,2]</sup>. There are few specific reports about how to deal with aortic hemorrhage quickly and effectively during sternotomy in redo aortic surgery. This study summarizes clinical data of patients with sternotomy hemorrhage in redo aortic surgery, as well as the relevant clinical experience with femoral-femoral bypass and hypothermic circulatory arrest.

## METHODS

We selected a total of 11 patients treated at the Department of Cardiovascular Surgery of Shanghai DeltaHealth Hospital who underwent redo aortic surgery and developed sternotomy hemorrhage from May 2018 to August 2021 (Table 1). All cases were diagnosed based on clinical manifestations, electrocardiogram, echocardiography, and preoperative computed tomography angiography (CTA) (Figure 1), and femoral arteriovenous ultrasonography ensured the safety of femoral cannulation. The indications for redo aortic surgery are given in Table 1. This study was conducted in compliance with the tenets of the Declaration of Helsinki and was approved by the Ethics Committee of Shanghai DeltaHealth Hospital (SDH (2018) KYLWPJ 001). All patients provided written informed consent for using their clinical data for scientific presentations or publications.

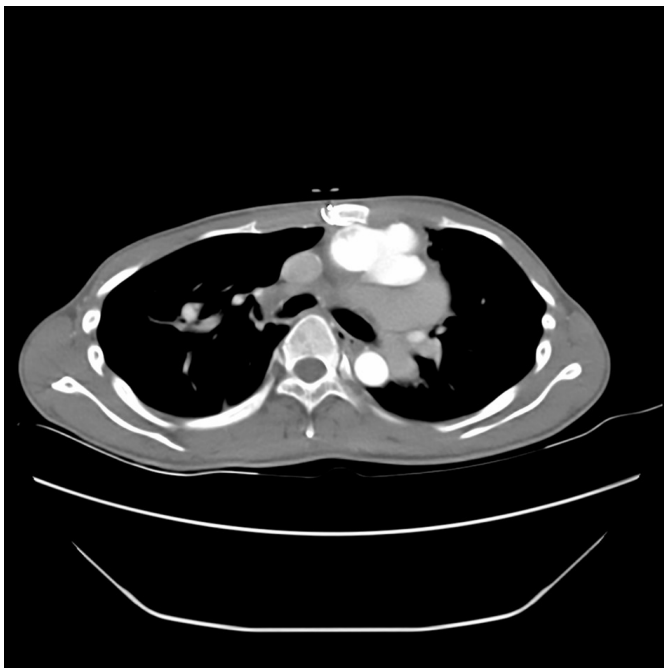
## Surgical Technique

Right femoral vessels were routinely prepared and exposed with a groin incision for percutaneous access, and heparin sodium (3 mg/kg) was injected into the central vein for systemic anticoagulation. An arterial cannula was inserted through the right femoral artery, and a venous drainage tube was inserted through the right femoral vein to establish cardiopulmonary bypass (CPB). Preoperative CTA demonstrated that aortic rupture during sternotomy could not be avoided in some patients (Figure 1); in these cases, the external transfer machine was directly cooled to 25°C, and a median sternotomy was performed. For patients with aortic valve dysfunction prior to surgery, the apex of the heart was exposed through a left intercostal incision and a 3-0 PROLENE™ line with a felt suture purse for transapical left ventricular drainage. In other patients, aortic bleeding during sternotomy was possible but not inevitable. These patients underwent free femoral arteriovenous cannulation prior to sternotomy in preparation for possible sternotomy hemorrhage. In case of arterial hemorrhage during sternotomy in both patient types, the sternum was clamped with towel forceps on both sides of the sternum to control the hemorrhage (Figure 2), and CPB was started quickly. Rapid infusion and cooling were performed, with an ice cap on the head, and the head in the down position. Based on the size of the aortic crevasses and the degree of difficulty of the surgical repair, either moderate hypothermic circulatory arrest (MHCA) or deep hypothermic circulatory arrest (DHCA) was performed. The aortic rupture was sutured, or the aortic crevasse was blocked with a balloon catheter. If the hemorrhage could not be controlled by the abovementioned methods, the aortic root was freed and blocked; if freeing the

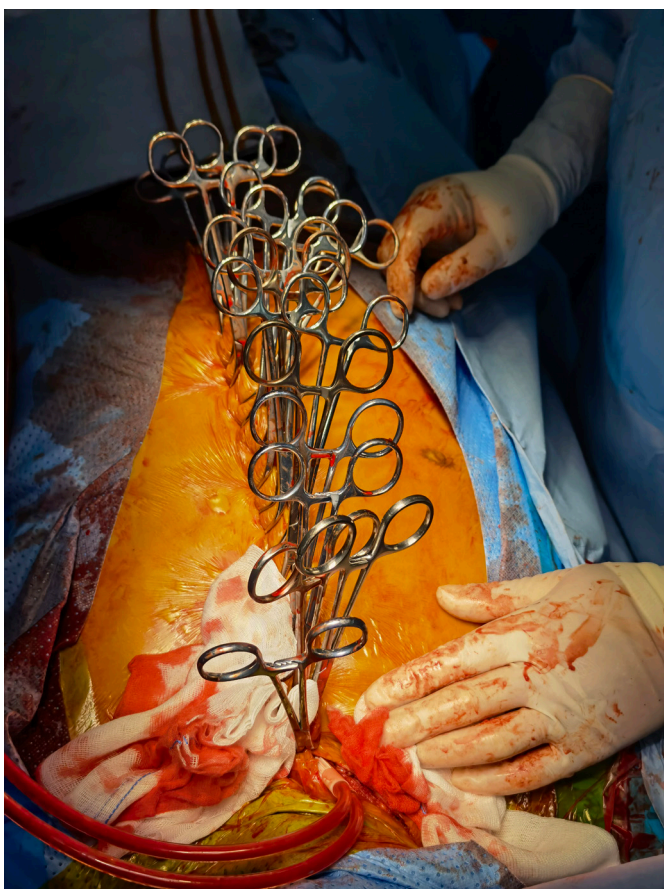**Table 1.** Patients' characteristics.

No.	Sex	Age (years)	BMI	Comorbidities	Previous surgery	Postoperative year	Reason for redo surgery
1	F	64	20.6	None	AVR	20	AV dysfunction
2	M	25	15.1	Cerebral infarction	Bentall procedure	7	Perivalvular leak, aortic pseudoaneurysm, HF
3	M	31	24.4	Hypertension	Bentall procedure	7	Aortic pseudoaneurysm
4	M	61	22.7	Cerebral infarction	AAR	7	Aortic pseudoaneurysm, MI, AI
5	F	46	26.1	Hypertension, DM	AAR	0.7	Chronic AD
6	M	55	21.6	Hypertension	AAR + semiarch replacement	12	Aortic pseudoaneurysm
7	M	66	24.3	Hypertension	AAR + semiarch replacement	9	AAA, AI, HF
8	M	27	25.7	Hypertension	Bentall procedure	4	AD + aortic arch aneurysm
9	M	26	17.3	None	Bentall procedure	0.2	Aortic pseudoaneurysm
10	M	30	18.1	None	AAR + arch replacement	0.5	Aortic pseudoaneurysm repair
11	M	56	24.9	Hypertension	AAR+TEVAR	14	Chronic AD

AAA=ascending aortic aneurysms; AAR=ascending aortic repair; AD=aortic dissection; AI=aortic insufficiency; AV=aortic valve; AVR=aortic valve replacement; BMI=body mass index; DM=diabetes mellitus; F=female; HF=heart failure; M=male; MI=mitral insufficiency; TEVAR=thoracic endovascular aortic repair



**Fig. 1** - Preoperative computed tomography angiography tridimensional image depicting aortic pseudoaneurysm adherent to the sternum.



**Fig. 2** - Sternum clamped with towel forceps on both sides to control hemorrhage.

aortic root was difficult, distal aortic anastomosis was performed by DHCA, then the artificial vessel was blocked after anastomosis. Once hemorrhage was controlled, circulation was restored, and a drainage tube was placed in the right upper pulmonary vein or at the apex of the heart. For mitral valve surgery, a superior vena cava cannula was routinely placed. For patients who required aortic arch replacement during surgery, routine right innominate artery cannulation was selected for cerebral perfusion. Intraoperative left common cervical cerebral perfusion was prepared depending on cerebral oxygenation. The specific surgical procedures performed on the 11 study patients are described in Table 2.

## RESULTS

The average interval between the patients' previous operation and their last operation was  $7.4 \pm 6.2$  years. Two patients required emergency surgery; the other patients underwent elective operations. Operations were successfully completed in all patients. The mean intraoperative hypothermic circulatory arrest time was  $8.8 \pm 7.1$  minutes, and mean rectal temperature was  $17.8 \pm 1.9^\circ\text{C}$ . Complications comprised one case of bleeding reoperation and two cases of postoperative tracheotomy. There were no postoperative cerebrovascular complications, paraplegia, low cardiac output, or other complications. Two patients died during hospitalization: one due to sudden refractory arrhythmia four days after operation, and the other from active rupture and hemorrhage of the descending thoracic aorta one month after operation. After discharge, the mean follow-up time was 23.4 months (range: 5-43 months), and there were two deaths. One patient died of a sudden intracerebral hemorrhage, and the other died of an infection. Of the remaining seven patients, two required thoracic endovascular aortic repair surgery at a later stage, and one developed high fever and *Staphylococcus aureus* in blood cultures one year after surgery. In the latter case, anti-infective treatment was administered for six weeks, and no fever occurred in the past year. All of these seven patients have recovered well up until the time of this writing (Table 2).

## DISCUSSION

For cardiac surgeons, redo aortic surgery is still a great challenge. One study reports that in 2555 patients who underwent redo cardiac surgery, compared with patients without injury during sternotomy, patients with injury had a higher early mortality (6.5% and 18.6%, respectively<sup>[1]</sup>), reducing the rate of redo aortic surgery. Complications and mortality associated with redo aortic surgery are urgent problems for cardiac surgeons.

In our center, all patients undergoing reoperation of the aorta underwent preoperative CTA to assess the risk of aortic rupture and hemorrhage during sternotomy, and to prepare relevant surgical plans. Studies have reported the importance of accurate preoperative assessment<sup>[3]</sup>. In this study, all patients were prepared for femoral vein cannulation before surgery, and for patients in which sternotomy hemorrhage could not be avoided, we used early cooling with CPB and reduced flow, followed by open sternotomy. It has been shown that preoperative femoral artery cannulation and sternotomy after femoral arteriovenous diversion can significantly reduce the risks associated with surgery and benefit patients<sup>[4,5]</sup>.

**Table 2.** Patients' surgical methods, blood component transfusions, and outcomes.

No.	Surgical options	HCA time (min)	Rectal temperature (°C)	Red blood cells (U)	Blood plasma (ml)	Blood platelet (U)	Complication	Follow-up
1	AVR	4	21.1	10	300	0	None	Alive
2	Cabrol procedure	2	24.2	2	0	0	Malignant arrhythmia	Dead
3	Bentall procedure	16	18.6	2	600	0	None	Alive
4	MVR + Wheat procedure	25	17.8	2	0	1	None	Dead (cerebral hemorrhage)
5	AAR + Sun's procedure*	8	19.7	12	1000	0	None	Alive
6	AAR + Sun's procedure	10	17.3	16	1800	2	Rupture of descending thoracic aorta, tracheotomy	Dead
7	Bentall + Sun's procedures	5	20.3	16	1400	0	Bleeding reoperation tracheotomy	Alive
8	AAR + Sun's procedure	2	20.5	0	200	0	None	Alive
9	Aortic pseudo-aneurysm repair	13	19	8	400	0	None	Dead (infection)
10	AAR + arch replacement	3	20.6	10	0	0	None	Alive
11	AAR + Sun's procedure	9	18.4	16	1200	0	None	Alive

AAR=ascending aortic repair; AVR=aortic valve replacement; HCA=hypothermic circulatory arrest; MVR=mitral valve replacement

\*Sun's procedure: total aortic arch replacement and frozen elephant trunk implantation

In cases of hemorrhage during sternotomy in redo aortic surgery, we currently use CPB for rapid cooling and circulatory arrest; the effect is satisfactory, with no cerebral complications and no paraplegia. Studies show that it is safe to stop the circulation for 15 minutes at medium and low temperatures (20.1–28°C) and for 30 minutes at deep and low temperatures (14.1–20°C)<sup>[6]</sup>. Svensson<sup>[7]</sup> performed a series of examinations on the use of DHCA in 616 patients undergoing aortic surgery and found a stroke rate of 7% and a mean DHCA time of 31 minutes (range: 7–120 minutes). Statistical analysis showed that DHCA times > 45 minutes and > 60 minutes were independent predictors of stroke and early mortality, respectively. Atik<sup>[8]</sup> summarized femoral arteriovenous diversion and used cooling with low flow or deep hypothermia to stop circulation during sternotomy, and no cases of sternotomy hemorrhage were found. For redo aortic surgery in patients with preoperative aortic valve insufficiency, if there is a risk of rupture after sternotomy, transapical left ventricular drainage should be performed in advance, so that the myocardium can be better protected during the process of circulatory arrest. Wakefield<sup>[9]</sup>

reported a patient with severe aortic valve insufficiency who underwent redo surgery and successful left ventricular apical drainage to prevent ventricular dilatation and dysfunction. Percutaneous intra-neck puncture was successfully used to place a retroperfusion catheter through the coronary sinus in the hybrid operation room, and an aortic balloon was placed through one side of the femoral artery for occlusion to avoid hypothermic circulatory arrest<sup>[9]</sup>. Mehta<sup>[10]</sup> reported patients with retrosternal aortic aneurysm by percutaneous cardioplegic arrest before repeat sternotomy to avoid hypothermic circulatory arrest. However, these methods are complicated and require multidisciplinary cooperation, which is not suitable for most hospitals.

Regional development has been unbalanced in China, and the volume of redo aortic surgery tends to increase. At present, our center mainly adopts femoral arteriovenous cannulation, rapid cooling, and hypothermic circulatory arrest for arterial hemorrhage during sternotomy in redo aortic surgery. The use of MHCA or DHCA should be determined based on the size of

the rupture, difficulty of repair, and surgical method utilized. If complicated with aortic regurgitation, and depending on the situation, apical intubation for left ventricular drainage should be prepared. In the future, hemorrhage during sternotomy in redo aortic surgery could be avoided with hypothermic circulatory arrest, which is the goal of cardiac surgeons.

### Limitations

This study had some limitations. First, a small number of patients were reported. Second, this was a retrospective study, and the data were obtained from a single institution.

### CONCLUSION

According to our clinical result of retrospective cases, we believe that the femoral-femoral bypass with hypothermic circulatory arrest technique is a safe and reliable method to use in cases of sternotomy hemorrhage during redo aortic surgery.

**Financial support:** The authors received Three New Projects of Yijishan Hospital Affiliated to Wannan Medical College (Y21020) for the research of this article.

**No conflict of interest.**

### Authors' Roles & Responsibilities

TT	Substantial contributions to the conception or design of the work; or the acquisition, analysis, or interpretation of data; drafting the work; agreement to be accountable for all aspects of the work in ensuring that questions related to the accuracy or integrity of any part of the work are appropriately investigated and resolved; final approval of the version to be published
CW	Substantial contributions to the conception or design of the work; or the acquisition, analysis, or interpretation of data; drafting the work; agreement to be accountable for all aspects of the work in ensuring that questions related to the accuracy or integrity of any part of the work are appropriately investigated and resolved; final approval of the version to be published
JL	Agreement to be accountable for all aspects of the work in ensuring that questions related to the accuracy or integrity of any part of the work are appropriately investigated and resolved; final approval of the version to be published
KJ	Agreement to be accountable for all aspects of the work in ensuring that questions related to the accuracy or integrity of any part of the work are appropriately investigated and resolved; final approval of the version to be published

WL	Agreement to be accountable for all aspects of the work in ensuring that questions related to the accuracy or integrity of any part of the work are appropriately investigated and resolved; final approval of the version to be published
WS	Revising the work critically for important intellectual content; agreement to be accountable for all aspects of the work in ensuring that questions related to the accuracy or integrity of any part of the work are appropriately investigated and resolved; final approval of the version to be published

### REFERENCES

- Park CB, Suri RM, Burkhart HM, Greason KL, Dearani JA, Schaff HV, et al. Identifying patients at particular risk of injury during repeat sternotomy: analysis of 2555 cardiac reoperations. *J Thorac Cardiovasc Surg.* 2010;140(5):1028-35. doi:10.1016/j.jtcvs.2010.07.086.
- Kindzelski BA, Bakaeen FG, Tong MZ, Roselli EE, Soltesz EG, Johnston DR, et al. Modern practice and outcomes of reoperative cardiac surgery. *J Thorac Cardiovasc Surg.* 2022;164(6):1755-66.e16. doi:10.1016/j.jtcvs.2021.01.028.
- Kirmani BH, Brazier A, Sriskandarajah S, Azzam R, Keenan DJ. A meta-analysis of computerized tomography scan for reducing complications following repeat sternotomy for cardiac surgery. *Interact Cardiovasc Thorac Surg.* 2016;22(4):472-9. doi:10.1093/icvts/ivv367.
- Yildiz Y, Ulukan MO, Erkanli K, Unal O, Oztas DM, Beyaz MO, et al. Preoperative arterial and venous cannulation in redo cardiac surgery: from the safety and cost-effectiveness points of view. *Braz J Cardiovasc Surg.* 2020;35(6):927-33. doi:10.21470/1678-9741-2019-0472.
- Merin O, Silberman S, Brauner R, Munk Y, Shapira N, Falkowski G, et al. Femoro-femoral bypass for repeat open-heart surgery. *Perfusion.* 1998;13(6):455-9. doi:10.1177/026765919801300609.
- McCullough JN, Zhang N, Reich DL, Juvonen TS, Klein JJ, Spielvogel D, et al. Cerebral metabolic suppression during hypothermic circulatory arrest in humans. *Ann Thorac Surg.* 1999;67(6):1895-9; discussion 1919-21. doi:10.1016/s0003-4975(99)00441-5.
- Svensson LG, Crawford ES, Hess KR, Coselli JS, Raskin S, Shenaq SA, et al. Deep hypothermia with circulatory arrest. Determinants of stroke and early mortality in 656 patients. *J Thorac Cardiovasc Surg.* 1993;106(1):19-28; discussion 28-31.
- Atik FA, Navia JL, Svensson LG, Vega PR, Feng J, Brizzio ME, et al. Surgical treatment of pseudoaneurysm of the thoracic aorta. *J Thorac Cardiovasc Surg.* 2006;132(2):379-85. doi:10.1016/j.jtcvs.2006.03.052.
- Wakefield BJ, Leone AJ, Sale S. Left ventricular apex venting in high-risk redo sternotomy with severe aortic insufficiency: a case report. *A A Pract.* 2018;10(1):16-9. doi:10.1213/XAA.0000000000000623.
- Mehta AR, Hammond B, Unai S, Navia JL, Gillinov M, Petterson GB. Percutaneous cardioplegic arrest before repeat sternotomy in patients with retrosternal aortic aneurysm. *J Thorac Cardiovasc Surg.* 2021;161(5):1724-30. doi:10.1016/j.jtcvs.2019.09.191.

